

# Interhemispheric relationships: the neocortical commissures; syndromes of hemisphere disconnection

R. W. SPERRY, M. S. GAZZANIGA\* and J. E. BOGEN\*\*

*California Institute of Technology, Pasadena, Calif.*

Until a few years ago, prevailing views regarding the syndrome of the corpus callosum in man were based very largely on the studies of Akelaitis and his co-workers (Akelaitis et al. 1942; Akelaitis 1944). Using a wide variety of tests Akelaitis examined a series of more than two dozen patients with partial and complete surgical sections of the corpus callosum and anterior commissure and was unable to find any consistent neurological or psychological dysfunctions that could be reliably attributed to the commissural sections. Symptoms such as unilateral astereognosis, alexia, agraphia, ideomotor apraxia (Sweet 1941), as well as apathy, amnesia, personality changes and related effects, that earlier had been ascribed to callosal lesions (Alpers and Grant 1931) seemed accordingly to be more properly explained in terms of the extracallosal cerebral damage that commonly accompanies lesions in the commissures. These Akelaitis reports in combination with confirmatory observations on absence of symptoms after callosum section in animals established the general doctrine of the 1940's and 1950's in which it was believed that behavioral deficits seen in connection with callosal

lesions are best ascribed to associated brain damage (Bremer et al. 1956). Meanwhile, the discrepancy between the enormous size and strategic position of the corpus callosum on the one hand and the observed lack of any important functional disturbance following its complete surgical section on the other remained during this period one of the more puzzling enigmas of neurology.

In a subsequent series of so-called 'split-brain' animal studies begun in the 1950's (Myers 1961; Sperry 1961) it became possible through utilization of various experimental devices and controls to eliminate some of the ambiguities in the earlier evidence and to find at last a considerable number of important functions mediated by the neocortical commissures. In brief these 'split-brain' studies, conducted mainly with cats and monkeys, showed that the neocortical commissures are necessary for the interhemispheric transfer of learning and memory and also for the interhemispheric integration of many sensory and motor functions that involved the left and right hands or paws, and the left and right halves of the visual field. By 1960 the broader features of the cerebral disconnection, or 'split-brain' syndrome, were well established with respect to subhuman mammals.

Not long thereafter comparable symptoms were observed in a human patient with cerebral

\* Now at University of California, Santa Barbara, Calif.

\*\* Ross-Loos Medical Group, Los Angeles, Calif.

neoplasm and callosal infarction (Geschwind 1962; Geschwind and Kaplan 1962) and in another patient with surgical section of the forebrain commissures (Bogen and Vogel 1962; Gazzaniga et al. 1962). Bolstered by these confirmatory observations in man, the emerging picture of the connectional role of the neocortical commissures seemed sufficiently validated that it might be used to settle at long last some of the many confusing contradictions in the clinical literature (Geschwind 1965). A return to some of the older views of Dejerine, Liepmann, and others seemed to be indicated at this point along with a corresponding rejection of the Akelaitis reports. It shortly became evident, however, that the long and complex controversy of the corpus callosum was not to be settled quite so quickly and that further significant swings in the pendulum of opinion were yet to come. During the past several years, further observation of additional human patients with surgical section of the forebrain commissures has brought a mass of new evidence and with it a further shift in the theoretical outlook on the callosum (Gazzaniga et al. 1965, 1967; Gazzaniga and Sperry 1967; Gazzaniga 1967; Sperry 1967; Sperry and Gazzaniga 1967).

This more recent evidence comes from the study of a series of patients of Dr. Philip Vogel in whom surgical section of the commissures was carried out to help treat severe convulsive disorders not controlled by medication (Bogen and Vogel 1962; Bogen et al. 1965). All of these patients had undergone, in a single operation, complete transection of the corpus callosum, the anterior commissure and the hippocampal commissure plus, in several individuals, the massa intermedia. The same operation had been carried out previously in many dozens of monkeys the results of which, along with the observations on callosum section in man, indicated that the behavioral outcome should not be seriously incapacitating (Sperry 1961). There was reason, further, to favor the single complete section over partial sections performed serially. It was hoped that this surgery might help to confine the epileptic seizures to one side and tend to preserve consciousness during

an attack, that it might enable the patient to take precautionary or control measures at the onset of a seizure, and that the severity and duration of the attacks might be reduced by the elimination of the commissural contribution to mutual reinforcement of seizures during the generalized phase, and especially during *status epilepticus*.

When the surgery proved effective in eliminating generalized convulsions in the first two patients it was subsequently employed in additional cases most of whom are still too recent to evaluate. Although the therapeutic effect has been mixed among the later patients of this series, the outlook continues to hold promise for selected severe cases.

Included among the earlier patients of the series were two individuals (N.G. and L.B.) in whom the postsurgical course was particularly smooth, postoperative functions relatively unimpaired, and in whom the extracallosal brain damage seemed to be at a minimum for the series. These two select patients have been tested most thoroughly and are given greatest weight in our present interpretation as outlined below on the supposition that they come closest to a pure hemisphere deconnection syndrome. In both cases, however, there is presumed to have been some epileptogenic cerebral damage stemming from birth injuries that may possibly have resulted in a less than average amount of lateral specialization in cerebral function. Because of the special weight given their symptoms in the present account, further details of the case histories of these two select patients are here provided as follows:

*Case history N. G.:* N. G. was born June 29, 1933, in the sixth gestation month, was in an incubator for some weeks, and on leaving the hospital weighed five pounds (2300 grams). In spite of this, she was considered normal in development until she began having convulsions at age eighteen, a year after she graduated from high school. Her condition worsened as described in a previous case report (Bogen et al. 1965) and she was admitted for cerebral commissurotomy. She was always right-handed and right-footed, as were both of her parents and all four grandparents. Evidence for preoperative brain damage included: repeatedly abnormal EEGs, sometimes suggestive of a left temporal focus; hypaesthesia to

pinprick in the left hand shortly after a seizure; and a one-centimeter mulberry size calcification beneath the right central cortex seen on skull X-rays. A right carotid angiogram was negative and a pneumoencephalogram showed minimal ventricular dilation bilaterally. Preoperative IQ was 73. Operation was uneventful except for division of a sizeable bridging vein draining the right parietal area. Recovery from operation was smooth, with intelligible speech on the second postoperative day and orientation for person and place on the third day. Since discharge she has remained convulsion-free and, although needing help from her husband the first year, has been able to take on full management of her household.

*Case history L. B.:* L. B. was delivered on May 15, 1952, by cesarean section (his mother's third such delivery). He weighed five pounds, was cyanotic and was in an Isolette for eight days. He was an active baby, sat alone at five months and stood with support at seven months, but did not walk unaided until eighteen months, at which time he weighed fifteen pounds and was already talking. The patient and both parents are right-handed; an older half-brother is left-handed. His first seizures occurred at age three and despite intensive efforts at control by medication these became progressively more frequent and severe as he grew older. In the year preceding operation (i.e. during 1964), he had over fifty generalized convulsions while taking phenobarbital, Mysoline and Elipten. Despite an IQ of 115 and home tutoring, his school grades deteriorated until he was failing in all subjects. Evidence for preoperative brain damage was restricted to the convulsions, which had no localizing feature except an occasional epigastric aura, and generalized abnormalities on repeated EEGs. Neurologic exams, skull X-ray, brain scan and bilateral carotid angiogram were negative, as had been an air study at age four. Operation was uneventful; there was relatively little retraction and no bridging veins were interrupted. He spoke readily on the first postoperative day, and by the fifth day was ambulatory and well oriented. In the first three years after operation, he had three generalized convulsions and eight left-sided jacksonian episodes without loss of consciousness. He returned to public school after a year away, one grade below his age level and has since done passing work in all subjects except mathematics.

In many respects the difference between our current interpretation and that as seen three years ago would seem to reflect the differences in symptoms obtained with clean surgical sections per se, and those obtained with commissural lesions accompanied by additional and especially by progressive extracallosal cerebral damage. In contrast to the cerebral disconnection syndrome as recently depicted, these new

select cases are able, for example, to write meaningful material and perform written calculations with the subordinate hand. They draw with one hand the shapes of objects presented to the other hand or opposite half visual field. They locate with either hand points of tactile stimulation on the opposite half of the body. They carry out verbal commands with the subordinate hand; and they are not 'word-blind' and 'word-deaf' in the disconnected minor hemisphere. Whereas these and related observations tend to swing the over-all syndrome picture significantly back in the Akelaitis direction, there nevertheless remain certain important contradictions making our current interpretation described below a rather heterogeneous composite of earlier opinion. The general syndrome picture is still developing and it would be premature even now to attempt global value judgments regarding historic developments and contributions on the controversial issues involved.

### Disconnection symptoms

The most remarkable effect of sectioning the cerebral commissures continues to be the apparent lack of change with respect to ordinary behavior. The least affected of Vogel's patients, in whom complete section of the entire corpus callosum and anterior commissure was clearly visualized during surgery, exhibit no gross alterations of personality, intellect or overt behavior two years after operation. Individual mannerisms, conversation and bearing, temperament, strength, vigor, and coordination are all largely intact and seem much as before surgery.

Despite this outward appearance of general normality in ordinary behavior, distinct impairments are readily demonstrated with more detailed tests specifically designed to detect loss of interhemispheric integration. In general, the results of such specific tests indicate functional disengagement of the right and left hemispheres with respect to nearly all cognitive and other psychic activities. Learning and memory are found to proceed quite independently in each separated hemisphere. Each hemisphere seems

also to have its own conscious sphere for sensation, perception, ideation and other mental activities and the whole inner realm of gnostic experience of the one is cut off from the corresponding experiences of the other hemisphere — with only a few exceptions as outlined below.

For the sake of unity and convenience of description, the various disconnection symptoms that have been demonstrated to date are outlined below with specific reference where possible to a general testing unit that we have used

regularly for examining these patients illustrated in Fig. 1. The subject is seated at a table on which is mounted an adjustable shield that prevents the subject from seeing his hands or the test items on top of the table or the examiner and other equipment in the rear. The shield also serves to hold a white glass viewing screen for the back projection of  $2 \times 2$  slides in an automatic projector equipped with a mechanical shutter for quick-flash tachistoscopic presentation.

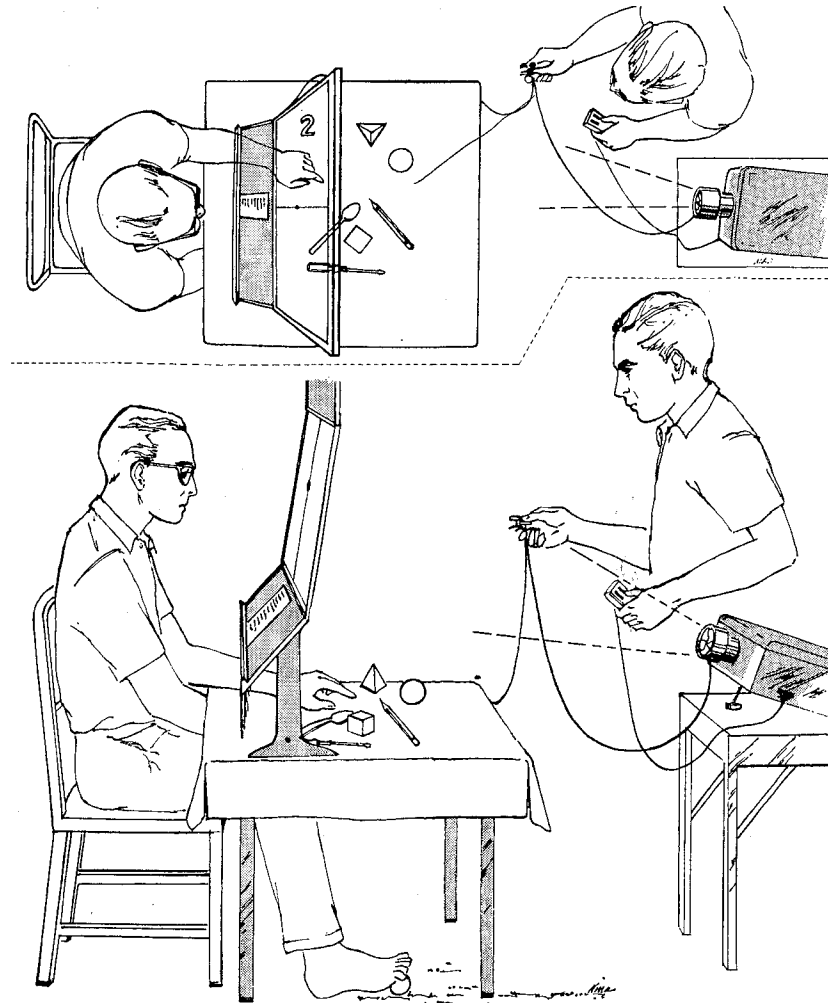


Fig. 1. Top and side views of basic testing unit used extensively to examine commissurotomy patients. Visual stimuli are back projected at  $1/10$  sec or less onto translucent white screen with subject's monocular gaze centered on designated fixation point. Moveable shield with fringe at bottom and table top with towel surface serve to exclude visual and minimize auditory cues.

## VISUAL SYMPTOMS

Visual material can be presented selectively to one or the other or both hemispheres as desired, by having the patient fix his gaze on a designated point on the viewing screen. Pictures of objects and other visual stimuli are flashed to the left and right halves of the subject's visual field using tachistoscopic exposure times of 1/10 sec or less. The brief exposure insures that stimuli intended for a given half-field will not be projected into the wrong hemisphere through scanning movement of the eyes. Visual material seen to the right side of the vertical midline is projected to the left hemisphere and vice versa.

Under these testing conditions vision in the commissurotomy patients has been found to be essentially normal in the right half-field. The patient reads and describes pictured material of various kinds in the right field at a level substantially the same as before surgery. When stimuli fall in the left field, however, in a random right-left presentation schedule, the subject's comments indicate he did not see the stimulus. If further questioned, he usually insists he saw 'nothing' or at most, a 'flash of light'. In literally hundreds of such test trials, conducted over the past three years, the commissurotomy patients have remained consistently unable to describe in speech or writing pictures or objects presented visually to the left side of the vertical meridian. This is not true if objects are merely held in the left field or shown with longer exposure times, presumably because very rapid eye movements bring stimuli on the left into the right half field. Failure to find the foregoing left field defect in the Akeleit studies seems best ascribed to the fact that tachistoscopic projection was not used in the visual testing.

Further analysis indicates that the difficulty in the left half-field in these patients is not a defect of vision but a defect in verbal communication resulting from the disconnection of visual function in the right hemisphere from the mechanisms for speech in the dominant left hemisphere. When simple manual or other non-verbal responses are used to demonstrate comprehension, it is clear that stimuli presented in

the left half-field are seen, and can be recognized, learned and remembered. Pictures of objects, geometric figures, colors, lines, dots, arrows in different directions, and the like, are recognized and correctly identified and described if the subject is allowed to communicate his understanding through nonverbal means. For example, the subject is able to point to particular features of a stimulus, to trace its outlines, to point out a matching or associated object, or to the correct name of the pictured object when shown a list of names. He can also pick out by touch an unseen object matching the one pictured from among a collection of other items. Whereas standard testing for vision in the left half-field may thus give an impression of hemiagnosia or even hemianopsia, tests employing nonverbal readout indicate retention of good visual function in the subordinate half-field.

An outstanding feature of visual perception in these patients is the independence of the two visual half-fields. Things seen in one half-field, that is in one hemisphere, remain dissociated in perception and memory from what is seen in the other half-field. If a word like *catkin* falls half in one field and half in the other, the two parts are perceived only as two separate words; the complete single word is never perceived as such unless the gaze is centered to left or right of the whole word. Things that have been seen previously are recognized and remembered on a subsequent presentation only if they are presented in the same half-field. When a given stimulus is presented in the opposite half-field, the patient responds as if it had not been seen on the previous occasion. Even in very simple tasks involving discrimination of gross color differences and simple directionality the patients showed no cross integration between what is perceived in one half-field and what is perceived in the other.

If a pair of objects or images is presented simultaneously, one to the left and one to the right visual half-field, and the subject is told to retrieve a matching object by touch with the left hand, the left hand picks out only the object pictured in the left half-field. If, before he can look at it, the person is asked what he has

chosen with the left hand, he responds with the name of the object seen in the other – the right – half-field (Fig. 2). This occurs even with gross discrepancies between the two objects. The right-left division of the visual field, as indicated in such tests, is abrupt at the midline without noticeable central sparing or overlap. Letters, dots or lines as close as one degree to the central fixation point on the left side are not included in the verbalized responses covering the right half-field and the converse is true of the manual readout for the left half-field.

A large variety of such visual tests point to the conclusion that in the absence of the commissures things seen in the left and right halves of the visual field are processed separately in the right and left hemispheres respectively. The normal interaction between elements within each half-field is preserved, but visual integration across the midline is eliminated. Each of the separated hemispheres has its own visual sensations, percepts, associated concepts and short- and long-term memories; the gnostic visual experiences of the one seem to have no direct contact with those of the other. In many ways it is as if two separate brains were viewing the left and right halves of the visual field, only one of which is able to communicate what it sees through speech or writing.

From the foregoing it seems evident that the commissures in the normal, intact condition subserve a large variety of visual functions, sensory-sensory, sensory-motor, and associational in nature. One of the most critical of these from the clinical standpoint is the integration of the visual functions of the minor hemisphere with the language and related comprehension and volitional mechanisms of the major hemisphere. The visual deficits resulting from cerebral commissurotomy do not cause much difficulty under ordinary conditions apparently because scanning movements of the eyes bring the contents of the left half of the visual world into the right visual field. Vision is further unified by the conjugate control of the eyes from each hemisphere along with other factors that tend to make each hemisphere view and attend to the same material all the time. Except in artificial testing situations, in which much care

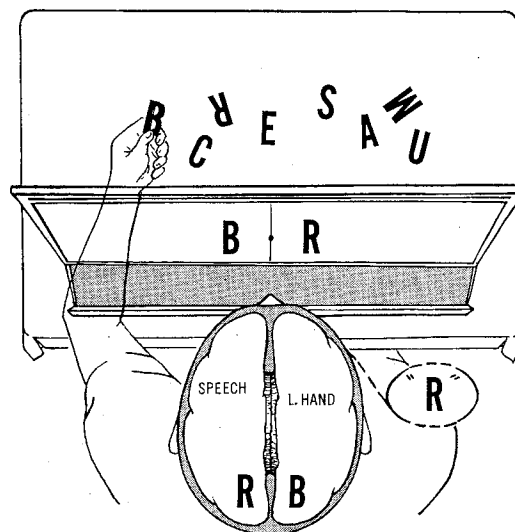


Fig. 2. When 2 letters, numbers, pictures of objects, or other stimuli are flashed simultaneously to left and right visual fields, subject denies seeing any but the *right* field stimulus. If seen stimulus is being retrieved by touch with left hand, however, subject consistently selects the letter or other item that matches the *left* field stimulus. When asked to confirm verbally what item was selected by left hand, subject names incorrectly the *right* field stimulus.

is taken to obtain a discretely lateralized visual input, there is generally a large common denominator of similar activity in each hemisphere.

#### SOMESTHETIC SYMPTOMS

Very similar symptoms are seen when the right and left hands are tested for stereognosis. In this case a variety of test objects are placed directly into each hand for recognition – the hands and test objects being screened from the patient's sight behind and under the shield (Fig. 1). Objects placed in the right hand are handled, named, and described in normal fashion. In contrast, attempts to name or describe objects held out of sight in the left hand consistently fail. Generally the patient can tell when something is placed in the left hand, presumably because of the presence of a weak ipsilateral cerebral projection in the somesthetic pathways. However, with objects in both hands, the pa-

tient usually denies even the presence of the left hand stimulus while describing that in the right hand. The major system appears to occlude the competing ipsilateral activity within the same hemisphere.

When an object is placed in the left hand alone, the subject tries to guess what it is, calling names for whatever comes to mind and using whatever clues are available. Auditory cues in particular must be carefully guarded against. Sounds of the moving fingers or finger nails, or movement of a ring against the surface of the test object or brushing of the object over a table surface may be sufficient to give the answer to the dominant hemisphere, especially where a small number of known objects is involved. When all such indirect sensory avenues to the dominant hemisphere were controlled, the present patients were unable to name or describe objects or any other complex stimulus patterns presented to the left hand. Why this symptom was not seen in the Akelaitis studies is not clear. Insufficient control of indirect cues might be the explanation.

It could be shown in respect to the left hand, as for the visual field, that the minor hemisphere can nevertheless perceive, recognize, learn and remember these same test items which the patient says he cannot feel. The patient can often demonstrate, by appropriate manipulation the use of a given test item such as a pencil, a toy pistol, a cigarette, a fork, etc., even though the attempt to name these same objects in speech or writing remains purely fortuitous. Also a given test item, after being felt with the left hand, can then be retrieved by blind palpation when placed in random position out of sight among a collection of other items. This is possible with delays imposed of several minutes or longer, i.e. the minor speechless hemisphere learns to recognize an object and retains the concept over a delay period well beyond the maximum level for delayed response in sub-human primates.

The most conspicuous symptom in the somesthetic sphere is this apparent astereognosis in the left hand that proves to be more exactly a unilateral *anomia*. This may be attributed to the break in communication between the left hemi-

sphere centers for speech and writing and those for the left hand in the right hemisphere. Other deficits, not involving speech, are also demonstrable. If the fingers of the left hand are touched lightly on the tip, middle or basal segment or at in-between points, the patient, with vision excluded, can easily locate the stimulated point with the tip of the thumb of the same hand. The normal person can also indicate with the opposite right thumb the corresponding mirror point in the opposite hand. Nearly all such cross-localization between the hands breaks down in the commissurotomed patient who is usually unable to cross-locate without vision even the correct finger, much less points within a finger. Similarly a posture imposed on thumb and fingers of one hand by the examiner cannot be copied in the opposite hand.

The lack of cross-integration for topognosis within the hand does not apply uniformly to the entire cutaneous half-field of the body. In the head and neck regions little or no breakdown of cross-integration is apparent owing presumably to strong bilateral representation of the head and neck in each hemisphere. Stimuli on the left as well as on the right side of the face are located, discriminated, and described verbally in speech or in writing. There is no unusual difficulty in naming objects placed in the mouth.

Over most of the torso and limbs, excluding the hands and feet, the situation tends to be intermediate. While verbal report is fairly good for localization on the left side, it is poor for even simple determinations of modality and position sense. More complex and refined discriminations, like the interpretation of skin writing or perception of shapes, which in the normal person exhibit cross-communication from left to right side, fail in the commissurotomed patient.

Cross-integration of stimuli from the hands themselves is severely impaired but not entirely eliminated — suggesting the presence of at least a weak system of basic sensory input from each hand to the ipsilateral hemisphere. Onset and presence or absence of tactile stimulation of the left hand can be reported verbally as can also a distinction between stimuli applied to the wrist or palm, thumb or palm, and thumb or little

finger. Sharp points that yield mild pain on pressure can also be detected by the major hemisphere. More refined discriminations fail, however, as between the fingers or between curved and straight lines drawn on the palm or even between crosswise and lengthwise movements of a stylus on the palm. Considerable individual variation is to be expected in the proficiency of these weak ipsilateral systems.

#### INTERMODAL ASSOCIATIONS BETWEEN TACTUAL, VISUAL AND AUDITORY SPHERES

If a picture of an object like an apple, a pencil, or an ashtray is flashed to the left half of the visual field, the commissurotomed subject can retrieve by touch the corresponding item from among an array of test objects out of sight. Unlike a normal person, however, the commissurotomed subject is able to do this only with the left hand when the visual cue is flashed to the right hemisphere, and it can be done only by the right hand when the visual input is in the right half-field (see Fig. 3). Conversely, if the object is first presented tactually to the left hand, the visual picture of the object is then identifiable only when it is seen in the left half visual field and vice versa. In the normal person, of course, visual identification under these conditions goes readily in either field.

The foregoing is consistent with the conclusion, supported by a wide variety of tests, that manual stereognosis for the left hand and visual perception of things in the left half of the visual field are both processed in the right hemisphere only. All such tests must be conducted with careful exclusion of secondary stimuli that are not confined to the intended manual and visual sensory fields. Objects that give off distinctive auditory cues like the jingle of a key case, the click or ring of a metal object, the rustle of a ball of tissue paper, etc., can subsequently be found and retrieved by blind palpation. This can be done by either hand indicating bilateral recognition and retention of the auditory percept by both hemispheres.

In summary, tasks that are dependent upon intermodal associations are possible only when

the sensory and related information is all projected into the same hemisphere. The cross-integrations between oppositely lateralized visual and somesthetic inputs that are easily carried out with the commissures intact are no longer possible.

#### SPEECH AND WRITING

Under ordinary conditions these patients give the impression of being able to converse and write at a normal level. As already explained, however, the right-handed commissurotomed patient is generally unable to express in speech or writing things seen in the left half of the visual field or felt with the left hand. By contrast, verbal expression is essentially normal as a rule for things perceived through the right half visual field and the right hand.

These and related observations support the conclusion that speech and writing in these patients are organized almost exclusively in the major left hemisphere, and that section of the commissures thus leaves the minor hemisphere

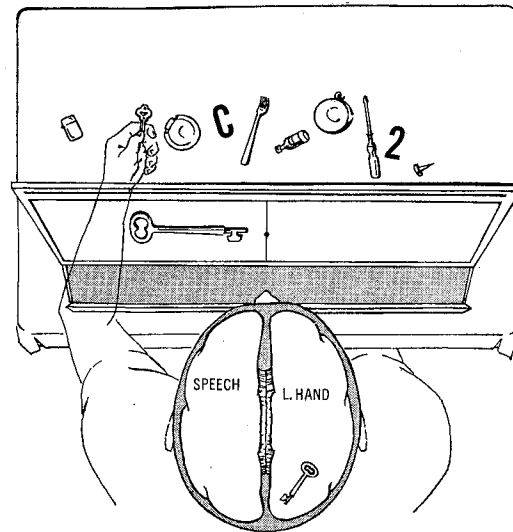


Fig. 3. Visuotactile associations succeed but only if visual and tactual stimuli both project to same hemisphere. Subject here denies seeing anything but a flash of light on left. However, if left hand is allowed to 'make a guess', correct object is selected or even an object 'used with' the projected stimulus if subject is so instructed.

speechless and agraphic. This conclusion may be extended to intermodal performances and to the general rule that speech and writing are possible for the conscious experience of the major hemisphere only. Speech in the minor hemisphere seems to be almost totally lacking in tests applied to date. However, the ability of the minor hemisphere to sing or to utter simple, familiar, or exclamatory words (Smith 1966), or to manage a little childlike writing in some cases cannot be excluded and remains to be explored.

#### CALCULATION

By one year after surgery these patients were carrying out mathematical transactions verbally and in writing, in testing sessions, in marketing, and in school work with a proficiency approximating the preoperative level. Difficulties in calculation are the rule in the first months after surgery. These difficulties may depend in part on diaschistic after effects as well as other factors including impairments in short-term memory and incomplete scanning of the visual fields all of which subside in time. More exacting measures of the upper level of attainment have yet to be made.

Tests for mathematical performance in the minor hemisphere with nonverbal readout and with the sensory input restricted to the left visual field or the left hand, indicate, by contrast, that the capacity for calculation on the minor side is almost negligible. By manipulating marbles or dowel sticks, watching spots of light flashed to the left field and pointing with the left hand, these patients may succeed in matching numbers or in adding one to numbers below ten but they fail when required to add or subtract two or higher numbers and they fail also at the simplest tasks in multiplication and division.

We have inferred accordingly that calculation, along with speech and writing, plus the visual functions associated with the right half-field, and the stereognostic functions of the right hand and all the associative and integrative activities dependent upon the foregoing are

organized predominantly in the major hemisphere. Further it would seem to be these activities of the major hemisphere that set nearly all the upper limits of behavior after commissurotomy and that are mainly responsible for the impression of near normalcy in ordinary behavior.

#### LANGUAGE COMPREHENSION IN THE MINOR HEMISPHERE

Symptoms seen in the first patient in this series were in conformity with the view that the minor hemisphere disconnected from the language centers of the major hemisphere is rendered 'word-blind', 'word-deaf', and tactually alexic (Geschwind 1965). This is not true of our later cases, however, in whom comprehension of both spoken and written words has been shown, although this comprehension is not demonstrable by verbal response.

*Auditory* comprehension of language was indicated by the ability of the subjects to retrieve with the left hand a particular object named aloud by the examiner and located out of sight among a collection of test objects. In such tests words like the following appear to be understood in the minor hemisphere: pyramid, cylinder, tack, coin, pliers, fork, flashlight, bulb, screwdriver, round, square, scissors, etc. This performance was frequently successful when the test object was not directly named but only indirectly described with definitions like: 'used to light fires with' for a *match*; 'a measuring instrument' for *ruler*, or 'liquid container' for a *glass*. Because tactual recognition with the left hand was shown to be a function of the minor hemisphere, it would appear that the names and descriptions of the test objects, and to some extent the verbal instructions, must have been heard and understood by this same hemisphere. Conversely, if an object were presented to the left visual field or the left hand, the subject could subsequently signal the name of the object when it was read aloud among a series of other names. The minor hemisphere in such tests seemed to have at least a moderate vocabulary. In these tests, however, the major hemi-

sphere also hears and comprehends the auditory material, and might therefore be suspected of aiding the minor hemisphere with feedback effects, subcortical sets, or other facilitative mechanisms.

Comprehension of *written* words in the minor hemisphere was demonstrated by similar procedures. After a printed word had been flashed to the left half visual field, the commissurotomy subjects were able to retrieve the corresponding item from among an array of objects by blind palpation with the left hand (Fig. 4). Conversely after a given test object had first been recognized with the left hand, the patient could look at a list of printed names or a series of names flashed successively to the left half-field and signal by pointing to the correct name of the test object. Control by the major hemisphere in these latter tests could be excluded because incorrect verbal descriptions given immediately after a correct response by the left hand showed that it was only the minor hemisphere that knew the answer.

The discrepancy between these findings and the accounts of 'word-blindness', and 'word-deafness' in the separated minor hemisphere remains to be accounted for. In part the discrepancy may stem from a failure in earlier studies to use nonverbal readout in testing for comprehension. Perhaps our subjects with early brain injury have a greater than normal bilateralization of the ability to comprehend words. Or it may be also that the disconnected minor hemisphere is capable of functioning at a higher level with the opposite hemisphere intact than where it must function in the presence of lesions on the opposite side. However, after surgical removal of the dominant hemisphere in an adult, language comprehension has been found to be far less impaired than expression (Smith 1966). It is further possible that in the presence of an aphasiogenic lesion in the left hemisphere, language comprehension by the minor hemisphere may be better in the absence of commissural influences. Only further observations can determine to what extent the picture described above represents a typical condition.

Tests involving comprehension and response to printed commands, in which the subject is

instructed to mimic or carry out simple acts indicate a much lower level of performance in the minor hemisphere. When verbs such as *smile, nod, frown, blow, point, wave, knock*, etc. were flashed to the left half-field, the patients were unable either to comprehend or to act, but did so readily from the right half-field. Lack of comprehension for the left half-field would seem to be the limiting factor in view of the subjects' inability even to point correctly to matching pen and ink sketches depicting these test words. The patients were, however, able to carry out the actions correctly when the sensory input consisted of these same sketches, instead of the words, flashed to the left field. The difference between names of objects and verbs remains to be explained. There is also a problem with regard to the role played by postoperative learning in the establishment of word comprehension in the minor hemisphere. At present the evidence favors the conclusion that the minor hemisphere possesses fair auditory comprehension but only an elemental reading vocabulary consisting mainly of object-nouns.

No deficits in language comprehension were demonstrated in the performance of the major hemisphere. These patients could read in the

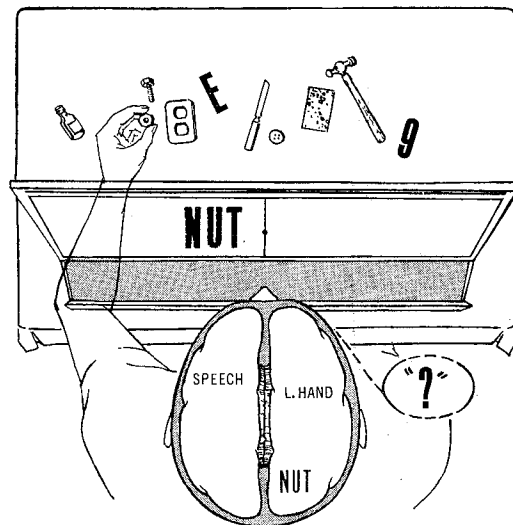


Fig. 4. Names of objects flashed to left half field can be read and understood but not spoken. Subject can retrieve the named object by touch with the left hand, but cannot afterwards name the item nor retrieve it with the right hand.

right half-field and were able to converse, carry out verbal commands, and write on a level not noticeably different from before surgery. However, tests for exact measurement of more subtle pre- and postoperative differences have yet to be carried out. The specific tests applied thus far have been aimed mainly at the minor side and have not taxed the capacities of the major hemisphere.

#### MOTOR FUNCTION

The nature and degree of praxic impairment was subject to large individual differences especially in the early weeks after surgery. At first the patients showed some left-sided apraxia to verbal commands. For example, commands such as 'raise your left arm', 'move your left foot' and 'make a fist with the left hand' could not be carried out. In one patient (L.B.) control for this type of movement was present already in the first postoperative day; in the majority it had returned by the end of the second week. In the other patients, the left-sided apraxia was more enduring and in one person (W.J.) the impairment is still present four and one-half years following surgery. During the initial period when the left-side apraxia to a verbal command was still present, the patients could usually carry out the required act if it was demonstrated by the examiner. To what extent this early deficit on the left side was caused solely by division of the commissures, or was dependent also on extracallosal damage is not settled.

In all cases there was gradual recovery of the lost motor control, but the recovery process varied considerably in its speed and in final extent in different individuals. In the two cases tested most intensively, the same type of dyspraxia was evident in the left hand when the information projected to the left hemisphere was nonverbal, as in drawing with the left hand the shapes of objects presented to the right hand or to the right half visual field. The fact that dyspraxia for verbal command is restricted to the left hand need not necessarily reflect unidirectionality associated with cerebral domi-

nance, in the commissural participation in praxis. It is the right hand which appears dyspraxic when certain constructional tasks are presented by nonverbal means, or when the right hand is responding to sensory input restricted to the right hemisphere. That is, praxic difficulties following division of the commissures may appear in either hand in those activities for which the ipsilateral hemisphere is specialized. Interpretation of the early post-surgical apraxia is further complicated by diaschistic, inflammatory, and other pathological factors. Hence, the gradual improvement in motor control may be attributed to a variety of factors, including subsidence of edema, recovery from diaschisis, and improvement of language comprehension in the minor hemisphere, as well as increased use of ipsilateral pathways. Accordingly, the following description is focussed on the more stable, long-term effects as observed mainly in the two select cases (N.G. and L.B.).

No basic motor impairment was evident in tasks where the motor control involved the main or contralateral system (i.e. the major hemisphere-right hand and minor hemisphere-left hand combinations). However, there was some tendency after surgery to use the left hand less than usual, under ordinary conditions. Special effort and stimulation was often necessary to bring the left hand into action. In general, motor symptoms were particularly evident in those activities in which a hemisphere was required to direct movement of the ipsilateral extremities. Good ipsilateral control was first attained for responses carried out by the axial and more proximal limb musculature. Thus responses that involved pointing to an object were performed well in the second month. After several months, most of the patients could form a variety of hand and finger postures, with either hand to verbal instructions. This included for example 'stick out your left middle finger', 'make a circle with your thumb and little finger', etc. Even writing with the left hand was possible when free shoulder movement was allowed, although the penmanship was crude compared to that of the right hand. Eventually the writing with the left hand could be per-

formed by L.B. with finger and wrist movement alone with the forearm fixed.

Crossed motor control is measured by flashing to right and left visual field outlined sketches of the hands and fingers in different postures (Fig. 5). The subject then mimics these with the hand on the same or opposite side. The responses break down in the commissurotomy patient when the hand response is on the side opposite the visual input. Again, simple postures, such as the closed fist or the open hand or the extended thumb can be achieved under these conditions by some patients, but more differentiated poses that are readily copied on the same side fail when the contralateral hand is employed. The deficit was especially marked when the nondominant right hemisphere attempted to control the right hand. Using this combination, the patients were usually unable even to make a fist or to merely spread out the fingers and hand as a whole. Whether the occasional success of the left hemisphere-left hand combination reflects ipsilateral corticospinal control of the forearm musculature remains unclear. It may be that these simpler movements follow in part as a natural conse-

quence of movement patterns initiated at the shoulder level.

What ipsilateral manual control was present seemed to be easily overpowered at any time by the contralateral system whenever the opposite hemisphere decided at the same moment to make a different movement in the same hand. In other words, the right hemisphere can direct the right hand toward a particular object only if the left hemisphere does not at the same time have contradictory information as to what it thinks the right hand ought to be doing. For example, a triangle flashed to the right hemisphere can be drawn by the right hand provided some other figure is not also flashed to the left hemisphere at the same time. In the latter case the right hand seems to be obliged to draw the figure seen by the left hemisphere. Again, activity in the contralateral system suppresses or cancels that in the weaker ipsilateral system.

Other problems in motor control arise when both hands are working together on the same or separate tasks. Inability to do two different things concurrently as in writing with the right and sorting cards with the left hand was stated to be the most consistent symptom in the earlier

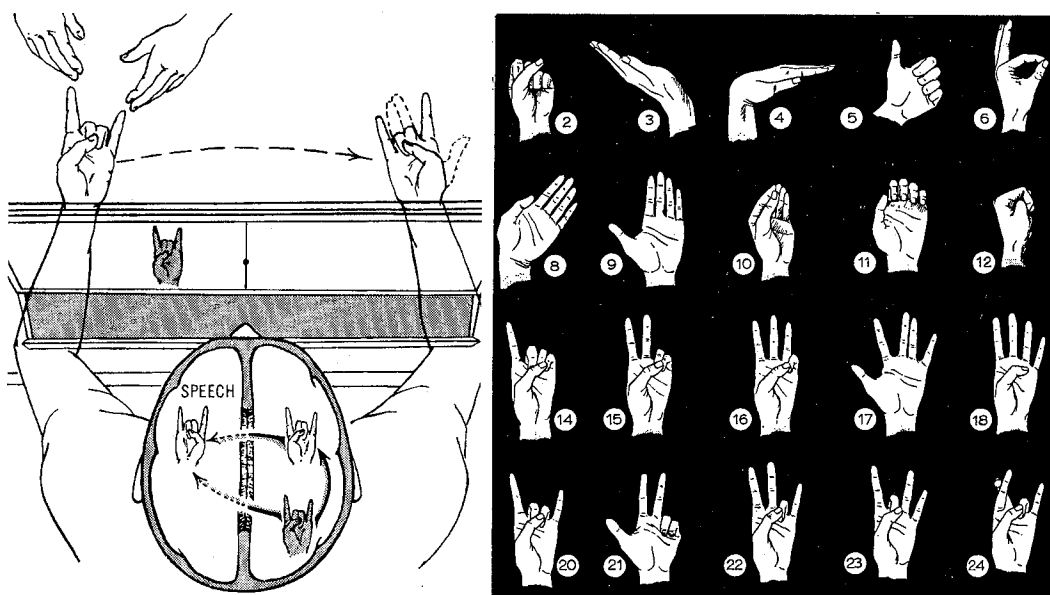


Fig. 5. One of a series of sample hand poses as shown above on right is projected in outline to right or left visual field and subject attempts to copy the posture with the homolateral and/or contralateral hand. The specific pose to be copied may also be impressed on one hand by examiner.

Akelaitis series (Akelaitis 1944). The present patients were fairly good at coordinate use of the two hands, as for example in catching thrown objects, or in judging two objects, and one of Akelaitis' cases could play the piano and type by touch after complete section of the callosum. In these latter activities both hands were presumably governed through the major hemisphere.

The capacity of either hemisphere, and particularly the left hemisphere, to control the ipsilateral as well as the contralateral arm accounts for many of the discrepancies between the present picture of the cerebral disconnection syndrome and that described a few years ago (Geschwind and Kaplan 1962; Gazzaniga et al. 1962) – like the ability to write and to carry out verbal commands with the subordinate hand, and to draw with one hand the shapes of objects presented to the other hand or to the opposite half visual field. Ipsilateral motor control and other less robust cerebral functions like language comprehension in the minor hemisphere appear to be more easily disrupted by extracallosal damage, leaving in control only the sturdier crossed systems.

It would seem reasonable to conclude from some of the foregoing that the initiation of voluntary responses was not restricted to the major hemisphere. However, the presence of speech, writing, calculation, the bulk of language comprehension, and the ideation dependent on all these, along with the motor and sensory representation of the dominant hand would strongly favor the left as the leading hemisphere. Except in those special testing situations in which considerable care was taken to evoke leading activity in the minor hemisphere, one had the impression that the separated major hemisphere was in command most of the time. Although good ipsilateral motor control of the left extremities was evident after commissurotomy, it did not fully return to the preoperative proficiency. It would thus appear that the callosum normally plays an important role in the control of hand movements that are directed from the homolateral hemisphere. The exact nature of the information transmitted across the callosum in such motor activity, as well as in its

various sensory and associational functions, remains to be determined.

#### MASKING OF DISCONNECTION SYMPTOMS IN ORDINARY BEHAVIOR

Whereas specific behavioral tests indicate, as described, a high order of mental activity in each of the disconnected hemispheres, and an almost complete functional separation of gnostic processes, remarkably little evidence of this splitting and doubling of the mental controls is apparent in general behavior. The great majority of the symptoms described above are readily concealed or compensated for, when the special restrictions of the testing procedures are lacking. The visual symptoms, for example, including the presence of two separate inner visual worlds is not apparent ordinarily to either the patient or an observer. These people do not complain spontaneously about a perceptual division or incompleteness in their visual experience, nor in all probability does the right hemisphere either experience a divided visual field. One can compare the visual experience of each hemisphere to that of the hemianopic patient who, following accidental destruction of one visual cortex or even hemispherectomy, may not recognize the loss of one half of visual space until this is pointed out in formal tests. The visual defects are only conspicuous when the visual material is flashed at 1/10 sec or less to prevent scanning by rapid eye movements.

Similarly the cross-integrative impairments in manual stereognosis are not apparent unless vision is excluded and auditory cues carefully controlled. Objects to be verbally identified must be kept away from the right hand and from the head and face. In many tests the major hemisphere must be prevented from talking and thus giving away the answer to the minor hemisphere through auditory channels. Similarly the minor hemisphere must be prevented so far as possible from giving nonverbal signals of various kinds to the major hemisphere. There are many indirect ways in which an informed hemisphere can cue in the uninformed hemisphere and hence conceal the commissural defect in unrestricted behavior.

Normal behavior under ordinary conditions is favored also by many other unifying factors. Some of these are very obvious – like the fact that these two separate mental spheres have only one body so they always frequent the same places, meet the same people, see and do the same things all the time and thus are bound to have a great overlap of common, almost identical, experience. The unity of the eyeball as well as the conjugate movements of the eyes causes both hemispheres to automatically center on, focus on, and hence probably attend to, the same items in the visual field all the time. Through sensory feedback a unifying body schema is imposed in each hemisphere with common components that similarly condition in parallel many processes of perception and motor action onto a common base. In motor control we have another important unifying factor in that each hemisphere can direct the movement of the ipsilateral hand and to an even greater degree the axial parts and proximal limb segments.

#### MENTAL PROPERTIES OF THE DIS- CONNECTED SUBORDINATE HEMISPHERE

The nature, level, and quality of mental awareness in the minor hemisphere can be inferred only indirectly. Markedly retarded in its comprehension of language and particularly in its linguistic expression, the subordinate hemisphere often gives an appearance upon cursory examination of being totally illiterate, imbecilic, and even agnostic. This is not the case, however, when the tests are so designed that the hemisphere is able to express its experience and understanding through nonverbal responses. Results obtained under these latter conditions suggest the presence of conscious awareness and intellect at a level characteristically human with fairly high order mental processes including abstract thinking and reasoning.

The minor hemisphere readily performs intermodal transfer tasks between vision, touch, hearing, and other modalities. An answer learned through auditory input, for example, is readily transferred into sight or touch, and vice

versa, at a level far above that attained by sub-human primates with brain intact. Such performances can be extended into associations for things that go together such as *nut* and *bolt*, *cigarette* and *ashtray*, etc. The presence of generalized concepts and ideas is demonstrated in similar responses in which the subject is able to search out with the left hand–right hemisphere combination an object only loosely described in terms of its use or purpose like ‘something to wash with’, ‘to light the stove with’, ‘to write with’, etc. These and other such performances that utilize sensory input to the minor hemisphere can be cross-checked against speech by the major hemisphere, so that when the subject is unable to confirm a successful trial verbally, there is clearly indicated a minor hemisphere performance.

As mentioned, the minor hemisphere can read printed names of objects as well as comprehend simple verbal instructions presented by ear. It is also able to spell simple 3 and 4 letter words when the 4 inch high, solid, cut out letters are presented in a scrambled pile to the left hand out of sight. After the left hand has succeeded in spelling words like *hat*, *cat*, *milk*, *coat*, etc., the subject is unable to name the words he has just spelled but can print the same word with the left hand, the entire performance being screened from sight throughout.

Under similar conditions the minor hemisphere can sort a scrambled pile of objects and assemble them into groups on the basis of shape, texture, surface, and function, demonstrating in the process a certain amount of logic and reasoning. In some tasks the minor hemisphere is superior to the major. Spatial constructions like drawing a box or a house or assembling patterns of painted blocks fall in this category (Bogen and Gazzaniga 1965). Rapid learning and fair memory are necessarily demonstrated in many of the foregoing tasks. If an array of ten different objects on a table top screened from sight are left in the same fixed position in the apparatus shown in Fig. 1, the commissurotomy subject quickly learns in a few trials with the left hand the spatial arrangement. The subject can then reach directly to each object when it is signalled to the right hemisphere.

The minor hemisphere also appears to possess distinctively human emotional sensitivity and expression. This is indicated in situations where information conducive to emotional response is restricted to the right hemisphere. Reactions of pleasure, annoyance, amusement, embarrassment, and the like, are evident in the facial expressions of the subject at times when the major hemisphere is ignorant of the cause and reason for these reactions. If the subject is asked at such a time why he is so pleased, annoyed, amused, or embarrassed he (the major hemisphere) is unable to explain and may resort to confabulation. It is interesting that an emotional tone generated in the minor hemisphere can spread into the opposite hemisphere. This we infer when the subjects verbalize the general emotional effect with words like 'nice', 'pretty', 'funny', or 'ugh!', but remain incapable at the same time of describing the particular stimulus that caused the reaction. It remains uncertain whether this inter-hemispheric transfer of emotion is effected through feedback from the periphery or via intact brainstem connections.

Further indication that the disconnected minor hemisphere is capable of the foregoing processes, operating by itself and not merely as an adjunct of the dominant hemisphere, is obtained in performances by the right and left hemispheres operating concurrently in parallel. Many of the foregoing right hemisphere activi-

ties can be carried out while the left hemisphere at the same time is performing a separate and different task of its own. Under certain conditions two tasks that ordinarily would tend to interfere with each other in the unified brain proceed with lessened conflict in the bisected brain (Fig. 6). It should not be inferred from this that the bisected brain is more efficient than the unified brain in any broad sense. In general these two parallel performances must be relatively simple individually and must be such that they can be carried out from a common posture and with a common mental set.

### Remaining problems

The foregoing stems from an attempt to explore rapidly some of the more salient features of the syndrome of the forebrain commissures. It is to be expected that additional functional deficits will continue to be demonstrated with further study. More intensive study in depth of the individual symptoms observed to date is needed throughout. More observation of additional cases is also needed before we can determine how typical the above picture may be, based as it is on two select patients, both with early brain injury, smooth recovery from surgery, and both with a minimum of postoperative impairment in unrestricted behavior.

Our primary aim has been to demonstrate that definite commissural symptoms are indeed present, correcting the earlier impressions to the contrary. There is need now for more exact delineation and measurement of these symptoms throughout. Additional impairments in more generalized capacities like learning, memory, intellect, creativity, initiative, reasoning, orientation, organizational ability, etc. are suggested in varying degree in the postoperative behavior of these patients. Definitive demonstration of these more subtle and general symptoms, however, must await further studies specifically aimed at such faculties and including comparisons with preoperative performance scores.

Existing information about the properties, capacities, and functional roles played by the




Fig. 6. Double reaction-time task involving discriminations for color in one hemisphere and for brightness in the other is performed as rapidly by commissurotomy patients as is either task alone.

minor hemisphere still leaves much to be answered (Mountcastle 1962; Zangwill 1964; Ettlinger 1965). There was no question but that in most of the postoperative tests administered, the right hemisphere has been decidedly less proficient than the left. The extent to which the comprehension of language in the disconnected minor hemisphere is a result of postoperative learning also remains a question.

The above description is to be applied with caution in other respects as well. It applies to a complete surgical division of the commissures in the presence of relatively little additional cerebral damage. Complications introduced in different types of clinical cases by partial, sequential, or progressive lesions of the commissures and also by different patterns of associated cerebral damage, when added to individual differences in asymmetry of both structure and function, along with other variables introduced by training, by age, native intelligence, and related factors add up to a variety of possible manifestations of symptoms in the clinic that become truly formidable in their complexity and diagnostic complications. In any practical application of the foregoing, allowances should be made accordingly and also for the great plasticity of the neocortical systems in general.

#### Addendum

Since the above was written, the testing program has been continued with studies still in progress on the same patients and also on 4 additional new patients of Dr. Vogel, all with the same surgery. The more recent findings confirm in the main the general syndrome as described above and extend its manifestations into olfactory and auditory modalities. The capacity for calculation in the minor hemisphere now appears to have been underestimated in the above, and some of the more elemental (midbrain) attributes of vision as well as of somesthesia have since been found to transfer across the midline. Otherwise the more recent developments are largely in the nature of individualized qualifications and natural extensions of the basic syndrome as described. Some

of these later details are included in subsequent publications (Sperry 1967a,b, 1968a,b; Gordon and Sperry 1968; Milner et al. 1968).

These more extended observations reveal an impressive array and range of individual variations for so small a patient series. Since these variations occur in both directions, i.e. toward greater and also toward lesser severity in different instances, the above account continues to stand as a reasonable average for the syndrome. At the same time the degree of individual variation as such would seem to reflect a high degree of functional plasticity in the commissural and related systems involved, particularly during developmental stages. Recent application of the above battery of tests to a patient with total agenesis of the corpus callosum disclosed almost none of the callosal symptoms produced by surgery in the adult (Saul and Sperry 1968). This patient, a college girl with a verbal IQ of 111 and with an average scholastic record, performed all the cross-integrative tasks described above at an essentially normal level.

In other kinds of performances, however, the congenital absence of the corpus callosum in this 'asymptomatic' patient appears to remain a definite handicap. She is subnormal in block design tests, in drawing, in spatial puzzles, and in a variety of perceptuomotor tasks. She is poor in arithmetic, especially geometry. Although she scores above normal in verbal reasoning, she is very low in non-verbal reasoning. In general the kinds of callosal functions that are not compensated, appear to be those associated with the lateral specialization of mental function. Selective impairment is found in those activities in which the specialized non-verbal and spatial faculties of the minor hemisphere would normally reinforce, complement and enhance the verbal and volitional performances of the major hemisphere. With verbal functions clearly favored in at least one (maybe both) hemispheres, the non-verbal, minor hemisphere faculties must remain either underdeveloped for having to share a verbally-committed hemisphere, or inadequately integrated with the verbal hemisphere – or both.

Studies in progress along with many incidental observations indicate that the above func-

tional syndrome that we see in this agenesis patient is present also in more exaggerated form in the commissurotomy patients. Marked impairments are evident in the same kinds of perceptuomotor, non-verbal and spatially-oriented tasks. The syndrome of hemisphere deconnection – the very existence of which in any form, was long in doubt – thus continues to grow the more we study it. Recent findings (Levy-Agresti and Sperry 1968) suggest the presence of basic organizational differences in the surgically disconnected hemisphere of a nature that would lead to active interference effects within the same hemisphere. A distinct strategic advantage can now be seen to having the verbal and non-verbal functions develop separately within different hemispheres.

Preparation of the manuscript and original work cited has been supported by grants to the first author from the National Institute of Mental Health (MH-03372) of the US Public Health Service and by the Hixon Fund of the California Institute of Technology.

## REFERENCES

- ALPERS, B. J. and F. C. GRANT: The clinical syndrome of the corpus callosum. *Arch. Neurol. Psychiat.* (Chicago) 25 (1931) 67–86.
- AKELAITIS, A. J.: Studies on the corpus callosum. VII. Study of language functions (tactile and visual lexia and graphia) unilaterally following section of the corpus callosum. *J. Neuropath. exp. Neurol.* 3 (1943) 226–262.
- AKELAITIS, A. J.: A study of gnosis, praxis and language following section of the corpus callosum and anterior commissure. *J. Neurosurg.* 1 (1944) 94–101.
- AKELAITIS, A. J., W. A. RISTEEN, R. Y. HERREN and W. P. VAN WAGENEN: Studies on the corpus callosum. III. A contribution to the study of dyspraxia and apraxia following partial and complete section of the corpus callosum. *Arch. Neurol. Psychiat.* (Chicago) 47 (1942) 971–1007.
- BOGEN, J. E., E. D. FISHER and P. J. VOGEL: Cerebral commissurotomy: a second case report. *J. Amer. med. Ass.* 194 (1965) 1328–1329.
- BOGEN, J. E. and M. S. GAZZANIGA: Cerebral commissurotomy in man. Minor hemisphere dominance for certain visuospatial functions. *J. Neurosurg.* 23 (1965) 394–399.
- BOGEN, J. E. and P. J. VOGEL: Cerebral commissurotomy: a case report. *Bull. Los Angeles neurol. Soc.* 27 (1962) 169.
- BREMER, F., J. BRIHAYE and G. ANDRÉ-BALISAUX: Physiologie et pathologie du corps calleux. *Schweiz. Arch. Neurol. Psychiat.* 78 (1956) 31–87.
- ETTTLINGER, E. G.: Functions of the corpus callosum. London, J. & A. Churchill Ltd. (1965).
- GAZZANIGA, M. S.: The split brain in man. *Sci. Amer.* 217 (1967) 24–29.
- GAZZANIGA, M. S., J. E. BOGEN and R. W. SPERRY: Some functional effects of sectioning the cerebral commissures in man. *Proc. nat. Acad. Sci.* 48 (1962) 1765.
- GAZZANIGA, M. S., J. E. BOGEN and R. W. SPERRY: Observations on visual perception after disconnection of the cerebral hemispheres in man. *Brain* 88 (1965) 221.
- GAZZANIGA, M. S., J. E. BOGEN and R. W. SPERRY: Dyspraxia following division of the cerebral commissures. *Arch. Neurol. (Chicago)* 12 (1967) 606–612.
- GAZZANIGA, M. S. and R. W. SPERRY: Language after section of the cerebral commissures. *Brain* 90 (1967) 131–148.
- GESCHWIND, N.: The anatomy of acquired reading disorders. In: J. Money, ed.: *Reading disability*. Baltimore, The Johns Hopkins Press (1962) p. 115.
- GESCHWIND, N.: Disconnection syndromes in animal and man. *Brain (Part 1)* 88 (1965) 237 and 585.
- GESCHWIND, N. and E. KAPLAN: A human cerebral deconnection syndrome. *Neurology (Minneap.)* 12 (1962) 675.
- GORDON, H. W. and R. W. SPERRY: Olfaction following surgical disconnection of the cerebral hemispheres. *Neuropsychologia (Oxford)* (1968) in press.
- LÉVY-AGRESTI, J. and R. W. SPERRY: Differential perceptual capacities in major and minor hemispheres. *Proc. nat. Acad. Sci.* 61 (1968) 1151.
- MILNER, B., L. TAYLOR and R. W. SPERRY: Lateralized suppression of dichotically presented digits after commissure section in man. *Science* 161 (1968) in press.
- MOUNTCASTLE, V. B., ed.: *Interhemispheric relations and cerebral dominance*. Baltimore, The Johns Hopkins Press (1962).
- MYERS, R. E.: Corpus callosum and visual gnosis. In: A. Fessard, ed.: *Brain mechanisms and learning*. Oxford, Blackwell (1961).
- SAUL, R. and R. W. SPERRY: Absence of commissurotomy symptoms with agenesis of the corpus callosum. *Neurology (Minneap.)* 18 (1968) 307.
- SMITH, A.: Speech and other functions after left (dominant) hemispherectomy. *J. Neurol. Neurosurg. Psychiat.* 29 (1966) 467.
- SPERRY, R. W.: Cerebral organization and behavior. *Science* 133 (1961) 1749–1757.
- SPERRY, R. W.: The great cerebral commissure. *Sci. Amer.* 210 (1964) 42–52.
- SPERRY, R. W.: Brain bisection and mechanisms of consciousness. In: J. C. Eccles, ed.: *Brain and con-*

- scious experience. New York, Springer-Verlag (1966) pp. 298-313.
- SPERRY, R. W.: Mental unity following surgical disconnection of the hemispheres (The Harvey Lectures). New York, Academic Press (1967a) Ser. 62.
- SPERRY, R. W.: Split-brain approach to learning problems. In: G. C. Quarten, T. Melnechuk and F. O. Schmitt, eds.: *The neurosciences: A study program*. New York, Rockefeller Univ. Press (1967b) pp. 714-722.
- SPERRY, R. W.: Hemisphere deconnection and unity in conscious awareness. *Amer. Psychologist* 23 (1968a) 723-733.
- SPERRY, R. W.: Plasticity of neural maturation. In: M. Locke, ed.: *Emergence of order in developing systems*. New York, Academic Press (1968b) in press.
- SPERRY, R. W. and M. S. GAZZANIGA: Language following surgical disconnection of the hemispheres. In: C. H. Milikan and F. L. Darley, eds.: *Brain mechanisms underlying speech and language*. New York, Grune and Stratton (1967) pp. 108-121.
- SWEET, W. H.: Seeping intracranial aneurysm simulating neoplasm. Syndrome of the corpus callosum. *Arch. Neurol. Psychiat.* (Chicago) 45 (1941) 86-104.
- ZANGWILL, O. L.: The brain and disorders of communication. The current status of cerebral dominance. *Res. Publ. Ass. nerv. ment. Dis.* 42 (1964) 103-118.